

ENDOVASCULAR MANAGEMENT OF GIANT SPLENIC ANEURYSM WITH ARTERIOVENOUS FISTULA

Wael Ibrahim, Hana Basourah,

1) Medical Imaging Department, Interventional Unit. King Fahad Specialist Hospital Dammam, Saudi Arabia

ARTICLE INFORMATION:

Article History

Received: 24 May 2012

Accepted in revised form:

24 November 2012

Published: 25 November 2012

Corresponding author:

Wael Ibrahim

e-mail: drwaelhamed@hotmail.com

Keywords:

Aneurysm, Splenic Artery, Fistula, Arteriovenous Fistula.

ABSTRACT:

Although splenic artery aneurysm is the commonest visceral and third most common intra abdominal aneurysm after aorta and iliac artery, aneurysm of splenic artery along with aneurysm of splenic vein and arteriovenous fistula is a rare entity. Most of them are <3 cm in diameter. Giant true splenic artery aneurysms are rare and very few lesions >10 cm have been reported. We report a case of an 11 cm x 8 cm size splenic artery and vein aneurysm with arteriovenous fistula. To the best of our knowledge, this is the 1st case of giant splenic aneurysm with arteriovenous fistula managed by endovascular treatment.

معلومات المقال

تاريخ المقال:

استلم في: 24 مايو 2012

قبل بعد المراجعة في: 24 نوفمبر 2012

نشر في: 25 نوفمبر 2012

المؤلف المسؤول: وائل ابراهيم

البريد الإلكتروني:

drwaelhamed@hotmail.com

الكلمات المفتاحية:

تمدد الأوعية الدموية، أم الدم، الشريان الطحالي، الناسور، الناسور الشرياني الوريدي.

الملخص العربي:

علاج التمدد الضخم لشريان الطحال من خلال الأوعية الدموية

وائل ابراهيم، هانا بصوره

قسم التصوير الطبي، وحدة التدخل، مستشفى الملك فهد التخصصي، الدمام، المملكة العربية السعودية

بالرغم من أن أم الدم الطحالي هو أكثر أنواع تمدد الشريان الحشوية، ويعد ثالث أنواع أم الدم البطني شيوعاً، بعد أم الدم الأبهرية و أم الدم الحرقفي، إلا أن تواجد أم الدم الطحالي الشرياني مع أم الدم الطحالي الوريدي ووجود ناسور بينهما يعد أمر نادر، وفي معظم الأحيان يكون قطر هذا النوع أقل من 3 سم. كما يندر تمدد الشريان الطحالي بشكل كبير، وهناك قلة قليلة من هذا النوع تتجاوز 10 سم تم حصرها. نحن نقدم حالة نادرة لأم الدم الطحالي الشرياني والوريدي بطول 11 سم وعرض 8 سم مع وجود ناسور بينهما وهما حسب أفضل علمنا تعد أول حالة من هذا النوع يتم علاجها عن طريق علاج الأوعية الدموية التداخلي.

INTRODUCTION:

Splenic artery aneurysms are the most common splanchnic artery aneurysms, representing 60% of such lesions¹. They are also the third most common intra-abdominal aneurysms after aorta and iliac arteries². Reported risk of rupture varies from 3% to 9.6%, more significantly, 95% of splenic artery aneurysms discovered during pregnancy are ruptured, resulting in a disproportionately high maternal and fetal mortality rate³. Most of these aneurysms are small and saccular, 80% are located in mid or distal splenic artery⁴. On the other hand splenic arteriovenous fistulae are rare. They can result from spontaneous rupture of a splenic artery aneurysm into vein or may occur as a complication of splenectomy. The first published report was by Weigert in 1986. There are around 70 reports describing more than 75 cases, which have been published in world literature⁵. Giant aneurysms have rarely been reported. We present a patient whose characteristic feature combined arterial and venous aneurysm associated with a hilar arteriovenous communication.

CASE REPORT:

A 37 years old woman who had 4 children the youngest is 4 months old; she was referred to our institution with diagnosis of splenic artery aneurysm associated with?? Arteriovenous fistula, she gave history of 5 months vague left upper abdominal pain and tender swelling, on examination her pulse, blood pressure, and respiratory system were normal. Abdomen was lax with

tender palpable left upper abdominal mass, a loud machinery murmur heard over left upper quadrant. Her hemoglobin, Platelet count, white blood cells and liver function tests were all within normal limit. She gave no history of abdominal trauma, no other gastrointestinal complaint. Triphasic CT abdomen showed aneurysmal dilatation of distal splenic artery close to hilum measuring 2.2cm x 1.7cm with splenic vein aneurysmal dilatation measuring 9cm x 8.9cm subsequent to existing arteriovenous fistula. Portal vein was enlarged at arterial phase denoting arterio-portal shunt, after diagnosis was confirmed, a multidisciplinary discussion between vascular, hepatobiliary, and general surgery with interventional radiologist supported the surgical management which was refused by patient and she preferred the second option of endovascular management. Under general anesthesia, 6 F access sheath was introduced through right common femoral artery, non selective abdominal angiogram was obtained, to identify the celiac trunk, splenic and hepatic arteries, with delayed images for portal vein, the digital subtraction angiography (DSA) images were obtained at the rate of 2-3 frames/s. Non-ionic contrast agents (Ultravist R [iopromid] 370 IU per 100 ml, Schering-Germany) were administered using automatic injector.

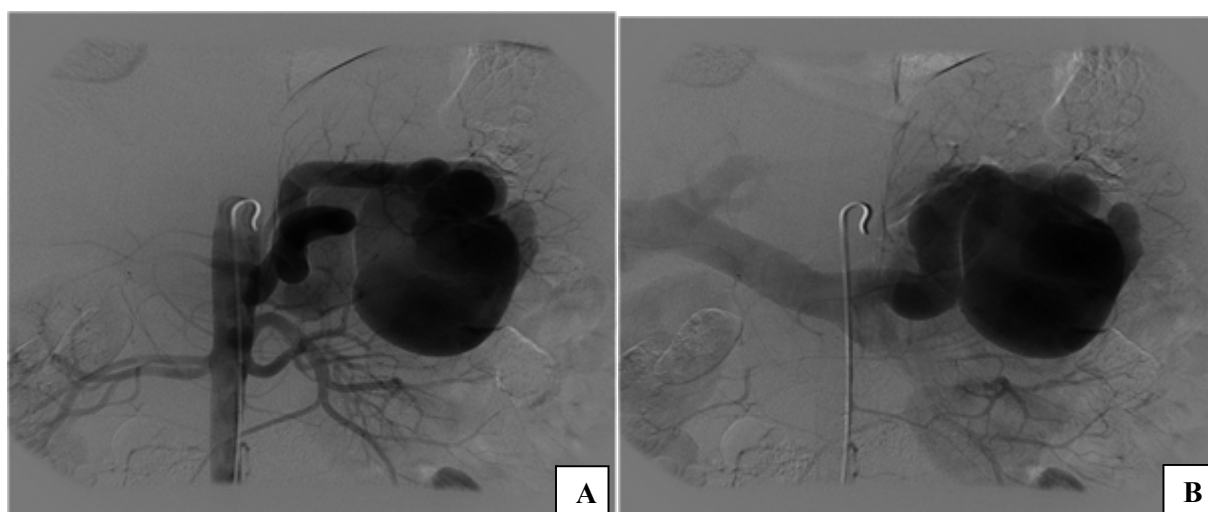


Figure1. A. Abdominal aortogram revealed dilated tortuous splenic artery with distal arterial saccular aneurysm and huge splenic vein aneurysm subsequent to arteriovenous fistula. B. Delayed images shows huge splenic vein aneurysm early opacified dilated portal vein.

Selective celiac trunk catheterization was performed followed by selective catheterization of splenic artery using C2 Cobra catheter (Johnson and Johnson, Cordis, USA) which placed at proximal part of splenic artery, selective splenic angiogram was done which showed, tortuous splenic artery with distal saccular aneurysmal dilatation, huge dilatation of splenic vein and early opacified dilated portal vein, Fig1. repeated angiograms were done at different angles with 6 frames/second aiming to assess the arteriovenous fistula however we could not clearly

delineate it due to very high flow through arteriovenous fistula. C2 cobra catheter was exchanged with 6 F Envoy guiding catheter (by Johnson and Johnson, Cordis, USA), through which 10 mmx4cm balloon was advanced to proximal splenic artery, and temporary splenic artery occlusion was done by balloon inflation, angiogram was repeated through occlusive balloon and clearly delineated the wide neck arteriovenous fistula, Fig2.

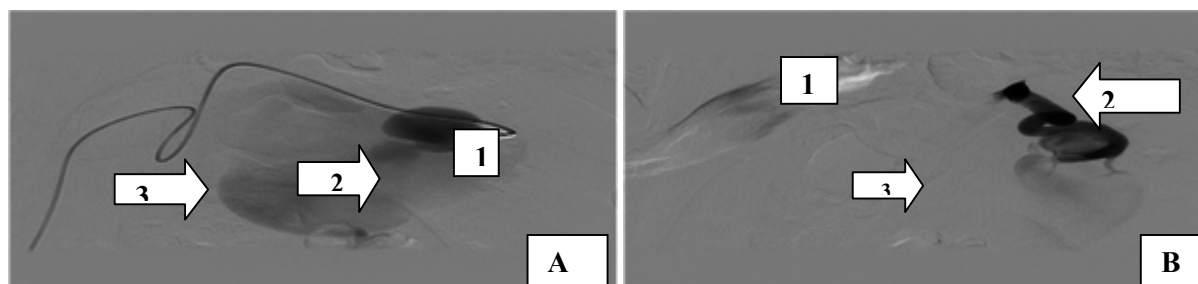


Figure2. A. Selective splenic artery angiogram 1. Splenic artery aneurysm 2. splenic AVF 3. splenic vein aneurysm. B. Selective splenic artery angiogram through occlusion balloon (10mmx40mm balloon) showing 1. Site of occlusion balloon, 2. splenic arterial aneurysm, 3. Splenic AVF.

The existing tortuosity of splenic artery, as well as absence of distal landing zone omitted the possibility of using covered stent to occlude the existing fistula. Coil embolization of splenic aneurysm was decided however due to very high flow and wide neck arteriovenous fistula, there was high possibility of coil migration, splenic artery flow was again occluded by inflating balloon using 10mmx40mm balloon at its proximal part, through which multiple (n=8) 0.035 coils 12mmx14cm (Fibered Platinum Coils, Boston

Scientific Cork Ltd, Cork, Ireland) were deployed, at distal splenic artery distal to pancreatic branch and proximal to splenic artery aneurysm, Fig3. again the close proximity of aneurysm to hilum omitted distal coil deployment, occlusion balloon kept inflated for 5 minutes for securing coils position, angiograms were done through occlusion balloon before and after deflation which confirm total occlusion of distal splenic artery and successful embolization.

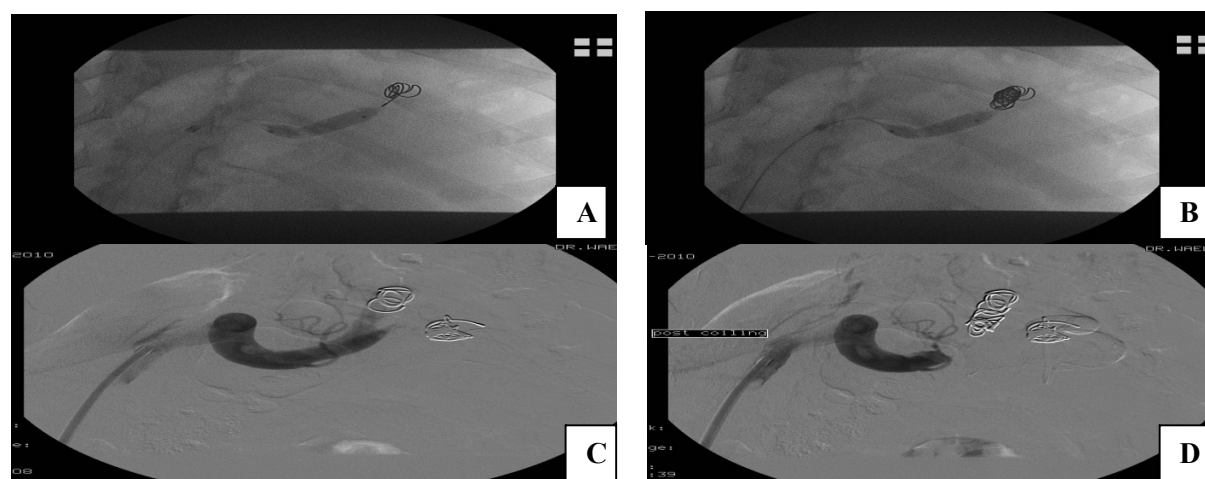


Figure 3 (A and B) Selective catheterization of splenic artery with guiding catheter through which occlusion of flow was done by inflating 10mmx40mm balloon. Through occlusive balloon multiple coils were deployed forming two baskets of embolizing coils. (C and D) angiogram was done after coiling showing partial occlusion at C and complete occlusion at D

Patient was shifted to ward, 2 hours before angiogram patient received 1 gram of cefazolin which also repeated immediately after procedure; no significant complications were encountered apart from left sided minimal effusion which detected 2 days post procedure and required no medical intervention. Follow up Doppler scanning was done twice and revealed patent portal vein with occluded distal part of

splenic artery as well as splenic vein aneurysm, patients was discharged after 5 days. Two weeks later CT of abdomen showed complete occlusion of distal splenic artery, non opacified thrombosed aneurysm with multiple patches of splenic infarctions. Follow up CT after 1 year revealed again totally thrombosed distal splenic artery with remarkable improvement of previously detected splenic infarctions, Fig4.

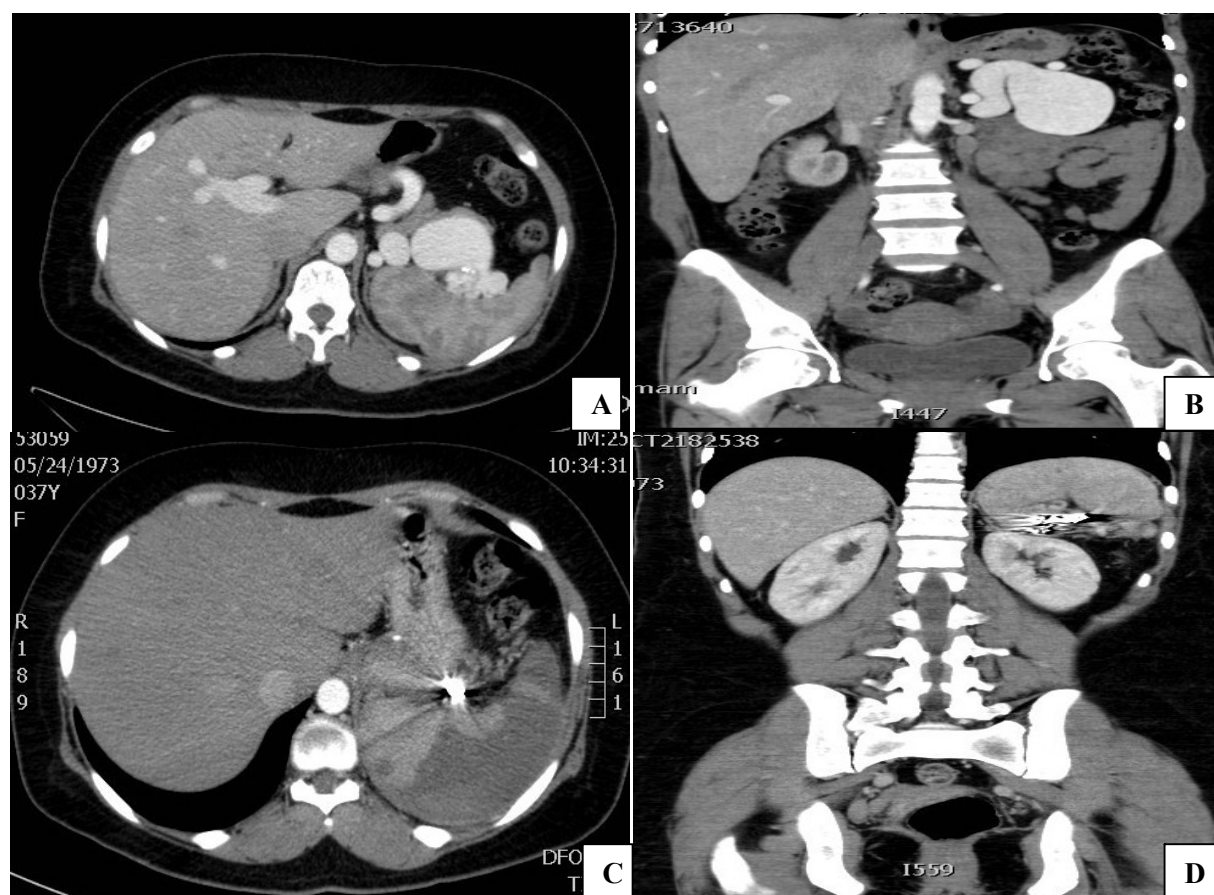


Figure4. CT Abdomen with contrast (A: axial scanning, B: coronal reconstitution) showing huge splenic artery and venous aneurysm, (C) 2 weeks post embolization axial CT scan with contrast showing post embolization segmental splenic infarction, (D) one year post embolization CT abdomen showing totally absent aneurysm with preserved spleen.

DISCUSSION:

Splenic artery aneurysms when present are commonly related to branch origins. Those less than 2 cm in size can probably be ignored. Splenic arteriovenous fistulae are commonly due to spontaneous rupture of a pre-existing splenic artery aneurysm into splenic vein. They are considered either congenital or acquired in origin, and mostly occur in women of childbearing age with a history of multiparity. The majority of traumatic splenic arteriovenous fistulae occur during splenectomy. Post-traumatic arteriovenous fistulae usually follow blunt trauma, and usually occurs within one year of trauma. However, artery aneurysm with AVF measuring

18cm x15 cm, patient was nulliparous, had never been pregnant and she had no history of abdominal trauma⁶. Giant aneurysms of splenic artery (diameter ≥ 10 cm) are exceptional. Only 12 cases have been reported so far in English literature⁷. First reported by Beaussier in 1770. The precise mechanism of its formation is unknown; however it has been associated with a number of conditions, most common with pregnancy and portal hypertension. Other conditions include systemic hypertension, atherosclerosis, medial fibro dysplasia, systemic infection, and various congenital diseases⁸. None of these known etiologic factors was present in our patient. Giant

splenic aneurysms are rarely asymptomatic, abdominal pulsatile mass and bruit is usually the presenting symptoms. Patients suffering from splenic arteriovenous fistulae are characterized by effect of portal hypertension. An evaluation of 31 cases described in literature showed that symptoms such as splenomegaly (around 55%) barometric portal hypotension (45%), esophageal varices (52%), gastrointestinal bleeding (45%), ascites (35%), and diarrhea (19%) were observed. The most frequently observed symptoms were machinery-type bruit over left flank. It has been also reported a lifetime risk of rupture of 2%-10% with an associated mortality of 25%⁹. These rates increase remarkably among pregnant women whereas the estimated risk of rupture can reach up to 50% with related maternal and fetal mortality of 70% and 75% respectively¹⁰. The rupture may take place either into gastrointestinal tract and peritoneal cavity or into splenic vein resulting in splenic arteriovenous fistula development. It is well known that the nidus of AVMs is fundamentally a conglomeration of arteriovenous fistulae¹¹. In 1993, Houdart et al¹², classified intracranial AVMs into 3 types based on the morphology of the nidus: arteriovenous, arteriovenous, or arteriovenous. In 2006 Cho SK, Do YS, et al modified this classification into 4 types according to their angiographic morphologies. Type I (arteriovenous fistulae) referred to at most 3 separate arteries shunted to a single draining vein, which is compatible with our case. Type II (arteriovenous fistulae) indicated multiple arterioles shunted into a single draining vein. Type III AVMs (arteriovenous fistulae) had multiple shunts between the arterioles and venules. In this type, if the fistula unit of the nidus was observed as a blush or fine striation on angiography, it was categorized as type IIIa for a non-dilated fistula; when the fistula unit of the nidus was observed as a complex vascular network, it was classified as type IIIb for a dilated fistula¹³. Although most reports have established diagnosis through abdominal arterial angiography, and selecting celiac axis which can elegantly demonstrate arteriovenous shunting, yet Ultrasound together with colored Doppler, Magnetic resonance and CT angiography also play important role as base line evaluation and for post management follow up. Splenic artery aneurysms should be promptly treated in high risk patients with symptomatic or expanding aneurysms, women of childbearing age and also patients undergoing liver transplantation¹⁴. Traditionally surgical resection with or

without splenectomy is employed in treatment of splenic artery aneurysms¹⁵, however, this patient carried a substantial risk owing to continuing variceal bleeding and high possibility of aneurysmal rupture during surgery. In addition, surgical approach of splenic arteriovenous fistulas presents often with technical difficulties because of distal site of the lesion, formation of adhesions and numerous portal collaterals. Laparoscopic treatments of common splenic artery aneurysms have been described, but to our knowledge, have not yet been used for treatment of giant lesions¹⁶. Non-surgical endovascular treatment of giant splenic artery aneurysms have been recently described; particularly for patients at high risk operative repair or those with lesions difficult to treat surgically, stent grafts have been used for exclusion of visceral artery aneurysms. This technique allows preservation of a continuous arterial access to spleen. The main caveat with these endovascular techniques is that they may be impractical for long and extremely tortuous lesions, so a stent graft well not be considered as a feasible solution mostly due to hilar presence of splenic fistula and tortuosity of splenic artery. A thirty six percutaneous catheter embolization of giant aneurysms and even ruptured giant aneurysms with metal coils, balloons, and sponges has been reported with favorable results¹⁷, with potential complications include pain fever, embolism to other visceral arteries, abscess formation, arterial disruption, contrast nephrotoxicity, incomplete occlusion and recanalization, despite these drawbacks, transcatheter embolization appears to have a lower incidence of serious complications compared with surgery, has a success rate of approximately 85%, and may even be considered as a first-line treatment in appropriate patients¹⁸. On the other hand it is less invasive, relatively low-risk, rapid procedure can be easily applied regardless location of vascular malformation and it does not necessitate splenectomy. These advantages of trans-catheter arterial embolization over surgery support strongly its efficacy in treating safely patients with splenic artery aneurysm complicated with arteriovenous fistula¹⁵.

CONCLUSION:

Giant splenic artery aneurysms are very rare; however the high risk of rupture demands rapid intervention. Endovascular techniques are efficient, of low risk and can be indicated in the majority of the patients especially for high-risk candidates and for aneurysms that are difficult to

treat surgically. Declaration of Conflicting Interests The author(s) declared no potential conflicts of interest with respect to the research, authorship, and/or publication of this article.

Funding.

The author(s) received no financial support for the research, authorship, and/or publication of this article.

REFERENCES:

- 1) Trastek VF, Pairolero PC, Joyce JW, Holler LH, Bernatz PE. Splenic artery aneurysms. *Surgery* 1982;91:694-99.
- 2) Lambert CJ, Williamson JW. Splenic artery aneurysm. A rare cause of upper gastrointestinal bleeding. *Am Surg* 1990;56:543-5.
- 3) O'Grady JP, Day EJ, Toole AL, Paust JC. Splenic artery aneurysm rupture during pregnancy. A review and case report. *Obstet Gynecol* 1997;50:627-30.
- 4) Shanley CJ, Shah NL, Messina LM. Common splanchnic artery aneurysms: splenic, hepatic, and celiac. *Ann Vas Surg* 1996;10:315-22.
- 5) Hung CF, Tseng JH, Lui KW, Wan YL, Tsai CC, Shem CH, Wu CS. Intractable oesophageal variceal bleeding caused by splenic arteriovenous fistula: treatment by trans-catheter arterial embolization. *Postgrad Med J* 1999; 75: 355-357.
- 6) Rajkumar Yadav, Et al, Unusually giant splenic artery and vein aneurysm with arteriovenous fistula with hypersplenism in a nulliparous woman, *Interactive Cardio Vascular and Thoracic Surgery* 2009; 8: 384-386.
- 7) Aditya Agrawal, Richard Whitehouse, Robert W. Johnson, Titus Augustine, Giant splenic artery aneurysm associated with arteriovenous malformation, *J Vasc Surg* 2006;44:1345-9.
- 8) Stanley JC, Zelenock GB. Splanchnic artery aneurysms. In: Rutherford RB, editor. *Vascular surgery*, 5th ed. Philadelphia: WB Saunders; 2000. p. 1369-82.
- 9) Kasir D, Macierewicz J, Castillo-Rama M, Singh S, Mackinlay J. Stent-graft repair of proximal splenic artery aneurysm. *Eur J Vasc Endovasc Surg* 2003; 6: 62-63 .
- 10) Selo-Ojeme DO, Welch CC. Review: spontaneous rupture of splenic artery aneurysm in pregnancy. *Eur J Obstet Gynecol Reprod Biol* 2003; 109: 124-127.
- 11) Tanaka R, Miyasaka Y, Fujii K. et al. Vascular structure of arteriovenous malformations. *J Clin Neurosci*. 2000;7:24-28.
- 12) Houdart E, Gobin YP, Casasco A. et al. A proposed angiographic classification of intracranial arteriovenous fistulae and malformations. *Neuroradiology*. 1993;35:381-385
- 13) Cho SK, Do YS, et al. Arteriovenous Malformations of the Body and Extremities: Analysis of Therapeutic Outcomes and Approaches According to a Modified Angiographic Classification. *J Endovasc Ther* 2006; 13: 527-538.
- 14) Robertson AJ, Rela M, Karani J, Heaton ND. Splenic artery aneurysm and orthotopic liver transplantation. *Transpl Int* 1999;12:68-70.
- 15) Kakizawa H, Toyota N, Naito A, Fukuda H, Ito K. Superselective transcatheter arterial embolization of a traumatic splenic arteriovenous fistula. *Radiat Med* 2004; 22: 364-367.
- 16) de Csepe J, Quinn T, Gagner M. The laparoscopic exclusion of a splenic artery aneurysm using a lateral approach permits preservation of the spleen. *Surg Laparosc Endosc Percutan Tech* 2001;11:221-4.
- 17) Hernandez-Lahoz I, Garcia-Casas R. Regarding "Giant splenic artery aneurysms: case report and review of literature." *J Vasc Surg* 2006;43:641.
- 18) McDermott VG, Shlansky-Goldberg R, Cope C. Endovascular management of splenic artery aneurysms. *Cardiovasc Intervent Radiol* 1994; 17:179-84.