

THE ROLE OF DIGITAL TREATMENT PLANNING IN MAXILLOFACIAL PROSTHETICS: A CASE REPORT

Mahmoud Elbashti, Yuka Sumita

Department of Maxillofacial Prosthetics, Graduate School, Tokyo Medical and Dental University (TMDU), Tokyo, Japan

ARTICLE INFORMATION:

Article History:

Received: 04 October, 2018

Accepted in revised form: 05 November, 2018

Published: 28 December 2018

Corresponding author:

Mahmoud Elbashti

E-mail: mahmmfp@tmd.ac.jp

Keyword:

Computer-aided design, computed tomography, photogrammetry, maxillofacial prosthesis.

ABSTRACT:

Advances in treatment planning have changed patients' expectations of the functional and aesthetic outcomes of maxillofacial prosthetic treatments. This case report describes and discusses the role of digital technology in the treatment planning of a facial prosthesis for a patient with complex maxillofacial prosthetic needs. A 75-year-old man was diagnosed with squamous cell carcinoma of the left maxillary sinus. The tumor was surgically resected and resulted in extensive tissue loss. The four key elements of visualization, design, manufacture, and evaluation were considered in digital treatment planning of the facial prosthesis; the first two are discussed in this report. The defect areas were three-dimensionally digitized using computed tomography and stereophotogrammetry. The scanned data were saved as a standard tessellation language file. From these data, virtual three-dimensional models were created for treatment planning options. With the aid of computer-aided design software, two types of facial prostheses were designed: an open-eye prosthesis and a closed-eye prosthesis. These designs were discussed with the patient to determine the one most suitable to meet his aesthetic expectations. Patients' expectations of treatment options can be improved through the virtual visualization and design offered by digital treatment planning. This case report confirms the applicability of digital treatment planning in managing patients with complex maxillofacial prosthetic needs.

معلومات المقال:

تاريخ المقال:

أستلم في: 4 أكتوبر 2018

قبل بعد المراجعة في: 5 نوفمبر 2018

نشر في: 28 ديسمبر 2018

المؤلف المسؤول:

محمود البشتي

البريد الإلكتروني: mahmmfp@tmd.ac.jp

الكلمات المفتاحية:

التصميم بمساعدة الكمبيوتر ، التصوير المقطعي المحوسب ، التصوير الفوتوغرافي ، تعويض الوجه والفكين.

الملخص العربي

دور تخطيط العلاج الرقمي في استعاضة الوجه والفكين: تقرير حالة

محمود البشتي، يوكا سوميتا

قسم استعاضة الوجه والفكين، جامعة طوكيو للطب وطب الأسنان، طوكيو، اليابان

التطورات في تخطيط العلاج غيرت من توقعات المرضى لنتائج المعالجة الوظيفية والجمالية لاستعاضة الوجه والفكين. هذا التقرير يصف ويناقش دور التكنولوجيا الرقمية في التخطيط العلاجي للتعويض الصناعي للوجه لمريض ذو احتياجات تعويضية معقدة للوجه والفكين. تم تشخيص رجل يبلغ من العمر 75 عامًا مصابًا بسرطان الخلايا الحرشفية في الجيب الفكي العلوي من الناحية اليسرى. تم استئصال الورم جراحيًا مما نتج عنه فقدان كبير للأنسجة. تم اعتماد على العناصر الرئيسية الأربعة لتخطيط العلاج الرقمي لاستعاضة الوجه والفكين والتي تشمل التصوير الرقمي والتصميم والتصنيع والتقييم. في هذا التقرير تم مناقشة العنصرين الأولين. تم تصوير المناطق المعيبة ثلاثية الأبعاد باستخدام التصوير المقطعي المحوسب والتصوير المجسم. تم حفظ البيانات المصورة ضوئيًا كملف بلغة التغطية بالفسيفساء القياسية. من هذه البيانات، تم إنشاء نماذج ثلاثية الأبعاد افتراضية لخيارات التخطيط العلاجي. وبمساعدة برامج التصميم الرقمية، تم تصميم نوعين من الأطراف الاصطناعية في الوجه: تركيبة تعويضية مفتوحة العين وتركيبية تعويضية أخرى مغلقة العين. تمت مناقشة هذه التصميمات مع المريض لتحديد الأنسب لتوقعاته الجمالية. يمكن تحسين توقعات المرضى من خيارات العلاج من خلال التصوير الظاهري والتصميم المتقدم لتخطيط العلاج الرقمي. يؤكد تقرير الحالة هذا على أهمية تطبيق تخطيط المعالجة الرقمية في إدارة المرضى ذوي الاحتياجات التعويضية المعقدة للوجه والفكين.

INTRODUCTION

Maxillofacial prosthetic rehabilitation is indicated for many patients with maxillofacial defects with functional and aesthetic deficiencies.¹⁻³ Rehabilitation requires complicated techniques to obtain functionally and morphologically satisfactory outcomes. The conventional protocol involves obtaining diagnostic models that represent the patient's defect, two-dimensional (2D) intra- and extra-oral radiography, and 2D photography. For good results, comprehensive diagnostic and treatment planning should be conducted before embarking on definitive rehabilitation.¹

Four key elements are considered in digital treatment planning for patients with maxillofacial defects: visualization, design, manufacture, and evaluation. Three-dimensional (3D) visualization of the defect can be achieved by medical imaging techniques such as computed tomography (CT),^{4,5} cone-beam computed tomography (CBCT),⁶ or magnetic resonance imaging (MRI),^{3,5} which all provide surface and deeper data, depending on the degree of segmentation. In contrast, non-medical imaging techniques such as stereophotogrammetry, which do not involve radiation exposure but may use lasers or intense light beams^{7,8} provide only surface data, onto which texture can be mapped to produce photorealistic 3D models. Three-dimensional design software plays an important role in treatment planning, offering comprehensive toolsets that allow sculpting of anatomical details and deformation of virtual clay models into any form required.⁹ The final prosthesis design can be virtually matched to the defect model and quickly evaluated for suitability before manufacture.

With advances in digital technology, rapid advances have been made in the treatment planning of maxillofacial prosthetics.^{10,11} This has changed patients' expectations of functional and aesthetic treatment outcomes. Digital treatment plans can easily be shown to the patient for approval or suggestion of modifications, and offers the patient a better understanding of the final results. This case report describes and discusses the role of digital technology in the planning of a facial prosthesis for a patient with complex maxillofacial prosthetic needs.

CASE REPORT

A 75-year-old man with squamous cell carcinoma of the left maxillary sinus was referred to the maxillofacial prosthetics clinic at Tokyo Medical and Dental University for rehabilitation. The left maxilla and ocular

globe had been surgically resected prior to external radiotherapy, causing extensive hard- and soft-tissue loss that affected oral function and aesthetics (Fig. 1). His chief complaints were aesthetic problems and loss of function, and he expected prosthetic rehabilitation to restore function, aesthetics, and participation in social activities. After a detailed discussion of the treatment process and examination of the defect area, the four key elements of digital treatment planning—visualization, design, manufacture, and evaluation—were considered. The first two are discussed in this report.

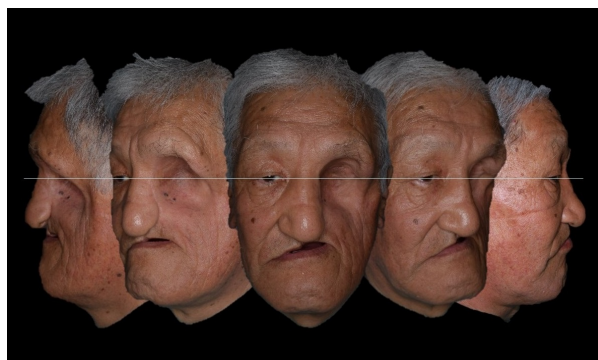

Fig 1. Two-dimensional image that enabled visualization of the facial defect of the patient, with different views.

globe had been surgically resected prior to external radiotherapy, causing extensive hard- and soft-tissue loss that affected oral function and aesthetics (Fig. 1). His chief complaints were aesthetic problems and loss of function, and he expected prosthetic rehabilitation to restore function, aesthetics, and participation in social activities. After a detailed discussion of the treatment process and examination of the defect area, the four key elements of digital treatment planning—visualization, design, manufacture, and evaluation—were considered. The first two are discussed in this report.

Visualization

The defect areas were three-dimensionally digitized using a routine post-surgical CT scan (SOMATOM Sensation 64-slice, Siemens AG, Erlangen, Germany). Data were saved in the Digital Imaging and Communications in Medicine (DICOM) file format, imported into Mimics 11.11 3D modeling software (Materialise NV, Leuven, Belgium) to produce a virtual model for both hard tissue (skull) and soft tissue (facial skin), and saved as a binary Standard Tessellation Language (STL) file (Fig. 2). Facial tissue was also digitized using 3D digital stereophotogrammetry (SCANIFY, Fuel 3D Technologies Limited, Oxford, UK; measuring accuracy 0.35 mm) (Fig. 3). The distance from

the digitizer to the object was 45 cm. The acquired point-cloud data were converted into a triangular mesh and saved as an STL file. From these data, virtual 3D models were created.

Three-dimensional Design

Three-dimensional models were imported into computer-aided design (CAD) software (Mimics). The facial midline was used as the axis of symmetry, and the normal-side image was mirrored to the defect side. The resulting model was saved as a separate STL file (Fig. 4). The defect model and mirrored model were then superimposed in Mimics, and the difference between the two datasets was masked as the new facial prosthesis data. At the same time, a 3D facial photograph was mapped on the CAD model using the photo-mapping function of Mimics (Fig. 5). Based on the 3D virtual design, two facial prostheses were designed: an open-eye prosthesis and a closed-eye prosthesis. These were discussed with the patient to determine the best option to meet his aesthetic expectations.

DISCUSSION

This case illustrates the role of digital technology in the treatment planning of maxillofacial prosthetics. The use of various digital technologies to visualize the defect and design of multiple prosthetic treatment options helped the patient understand the treatment plan and establish realistic expectations of outcome. Although the use of CT scanning as a visualization tool requires radiation exposure, it is a routine postoperative procedure for tumor recurrence screening in patients with neoplasms.¹² Despite issues relating to radiation exposure, artifacts, and scanning time, CT has the advantage of being able to scan deeper defects with shallow undercuts that cannot be visualized using other optical scanners.

Conventional methods of facial capture, such as facial impressions and plaster molding, are prone to inaccuracy, can be invasive, and can result in poor assessment and planning. Increasingly, 3D capture techniques are being used to generate more accurate records of complex facial geometry.¹³ Three-dimensional digital stereophotogrammetry allows rapid and simple capture of 3D colored models. The SCANIFY handheld 3D scanner enables quick collection of accurate data, which can help to reduce the patient's physical and psychological stress. In the present case, capturing the facial image and creating the 3D model took just 0.1 s and 30 s, respectively.

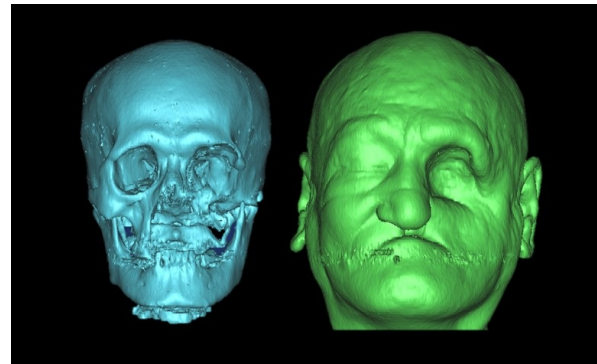


Fig2. Virtual 3D modeling of hard tissue (skull) and soft tissue (facial skin).

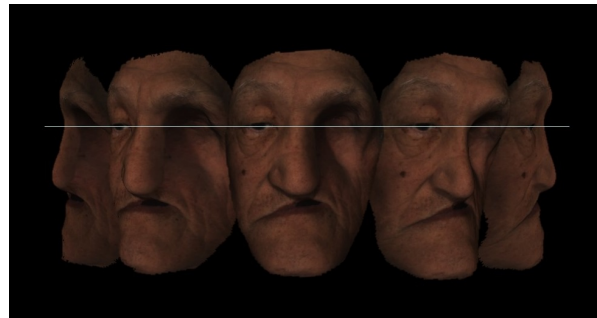


Fig3. Digitization of facial tissue by 3D digital stereophotogrammetry.

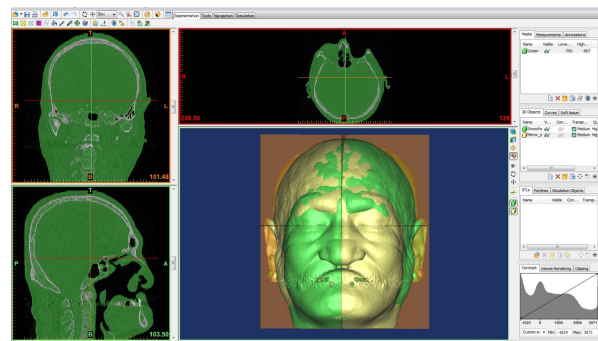


Fig 4. Mirroring of the normal side to the defect side based on the facial midline.




Fig5. Superimposition of the 3D digital photograph with the CT scan data.

In designing facial prostheses on a CAD model, the mirror image technique is commonly used.^{13,14} However, in patients with a large defect or deformation of residual soft tissue, construction of the facial prosthesis based on this technique may result in overextension of the prosthesis size to maintain symmetry. Here, Mimics' photo-mapping function was used to apply a digital photograph three dimensionally on the CAD model and confirm accurate positioning of the eye and external profile. This avoids having to shorten the CT to obtain an open-eye scan, as the patient's eyes must be closed during scanning. The final prosthesis image generated by Mimics is also effective for motivating patients. Patients' expectations of treatment options can be improved through the virtual visualization and 3D design offered by digital treatment planning.

REFERENCES

1. Beumer III J, Marunick MT, Garrett N, Rohner D, Reintsema H, Abemayor E, Penn R, Nabili V, Bucher P. Rehabilitation of Maxillary Defects. In: Beumer III J, Marunick MT, Esposito SJ, editors. Maxillofacial Rehabilitation: Prosthodontic and Surgical Management of Cancer-Related, Acquired, and Congenital Defects of the Head and Neck. 3rd edition. Chicago; Quintessence; 2011. P. 155-212.
2. Ariani N, Visser A, van Oort RP, Kusdhany L, Rahardjo TB, Krom BP van der Mei HC, Vissink A. Current state of craniofacial prosthetic rehabilitation. *Int J Prosthodont* 2013;26:57-67.
3. Elbashti ME, Hattori M, Sumita YI, Taniguchi H. Evaluation of articulation simulation system using artificial maxillectomy models. *J Oral Rehabil* 2015;42:678-84.
4. Jiao T, Zhu C, Dong X, Gu X. Rehabilitation of maxillectomy defects with obturator prostheses fabricated using computer-aided design and rapid prototyping: a pilot study. *Int J Prosthodont* 2014;27:480-6.
5. Coward TJ, Scott BJ, Watson RM, Richards R. A comparison of prosthetic ear models created from data captured by computerized tomography, magnetic resonance imaging, and laser scanning. *Int J Prosthodont* 2007;20:275-85.
6. Hatcher DC, Dial C, Mayorga C. Cone beam CT for pre-surgical assessment of implant sites. *J Calif Dent Assoc* 2003;31:825-33.
7. Sabol JV, Grant GT, Liacouras P, Rouse S. Digital image capture and rapid prototyping of the maxillofacial defect. *J Prosthodont* 2011;20:310-4.
8. Yoshioka F, Ozawa S, Okazaki S, Tanaka Y. Fabrication of an orbital prosthesis using a noncontact three-dimensional digitizer and rapid-prototyping system. *J Prosthodont* 2010;19:598-600.
9. Kim M, Lee J, Shin S. Fabricating an obturator using rapid prototyping to design the framework: A case report. *Int J Prosthodont* 2014;27:439-41.
10. Sykes LM, Parrott AM, Owen CP, Snaddon DR. Applications of rapid prototyping technology in maxillofacial prosthetics. *Int J Prosthodont* 2004;17:454-9.
11. van Noort R. The future of dental devices is digital. *Dent Mater* 2012;28:3-12.
12. Sullivan BP, Parks KA, Dean NR, et al. Utility of CT surveillance for primary site recurrence of squamous cell carcinoma of the head and neck. *Head Neck* 2011;33:1547.
13. Runte C, Dirksen D, Deleré H, Thomas C, Runte B, Meyer U, von Bally G, Bollmann F. Optical data acquisition for computer-assisted design of facial prostheses. *Int J Prosthodont* 2002;15:129-32.
14. Penkner K, Santler G, Mayer W, Pierer G, Lorenzoni M. Fabricating auricular prostheses using three-dimensional soft tissue models. *J Prosthet Dent* 1999;82:482-4.